15th International Symposium on Antimicrobial Agents and Resistance
ISAAR 2026
Fighting the Ongoing Pandemic of Antimicrobial Resistance
June 12 (Fri) - 14 (Sun), 2026 | Hong Kong Convention & Exhibition Centre, Hong Kong
www.isaar2026.org / www.isaar.org
HKSID HKSMI Annual Scientific Meetings
National Centre for Infectious Diseases NHG Health
Woodlands Health NHG Health

Repeat False-Negative HIV Tests in a Patient with HIV/AIDS

Yim Yee Ting Nicole[1], Maurice O'Kane[2], Lasantha Ratnayake[2], Ray Lin[2], Stephanie Sutjipto[1,2]
[1]Department of Infectious Diseases, Tan Tock Seng Hospital, Singapore
[2]Department of Infectious Diseases, Woodlands Hospital, Singapore

Background

False-negative human immunodeficiency virus (HIV) tests in patients with advanced HIV infection is rare, especially with 4th-generation tests. We report a case in Singapore where a patient presented with multiple opportunistic infections despite repeated negative HIV test results. We speculate that very high concentrations of p24 antigen and/or anti-HIV-1 antibody resulted in a high dose hook effect and false negative results, highlighting a rare phenomenon in 4th-generation HIV screening assays.

Clinical Case

A 59-year-old man presented to Woodlands Hospital, Singapore, in April 2025 with a 3-day history of fever, dyspnoea and cough. This was his fourth admission to hospital, in addition to 4 clinic presentations in 2025, which was attributed to infective exacerbation of previously well-controlled asthma.

Initial laboratory tests revealed a mild anaemia of 12.7 (13.6-16.6x10^9/L), lymphopenia of 0.7 (1.1-3.1x10^9/L) and C-reactive protein of 106 (0-5mg/L). COVID PCR and Respiratory Multiplex PCR (BioFire RP2.1) were negative. Initial chest X-ray showed mild airspace opacities in the left hilar region. Computed tomography (CT) scan of the thorax showed bilateral ground glass changes (Figure 1). Initial HIV screen was non-reactive (Signal to Cut-off ratio [S/CO] 0.56) on the BioRad Access HIV combo V2 assay. Further microbiology tests including sputum acid fast bacilli and tuberculosis polymerase chain reaction (PCR) tests, mycoplasma antibody, urinary Legionella and Pneumococcal antigens and sputum culture were negative. He also had a negative autoimmune screen. Sputum *Pneumocystis jirovecii* (PJP) PCR subsequently came back positive with low Cycle Threshold value. Examination revealed extensive oral thrush and some mucosal ulcers which returned positive for Herpes Simplex Virus.

Initiall impression was PJP pneumonia secondary to frequent steroid use from suboptimally controlled asthma. However, due to high clinical suspicion, CD4 and HIV-1 Reverse Transcription (RT)-PCR were sent, returning with a CD4 value of <20 and viral load of 666,000 copies/ml. A second HIV screen was negative again on the same assay; however was reactive using an alternative assay (Elecys HIV combi PT) with S/CO of 27.32. The initial HIV screen sample was re-analysed and following 1:2, 1:10 and 1:100 dilution, S/CO turned reactive.

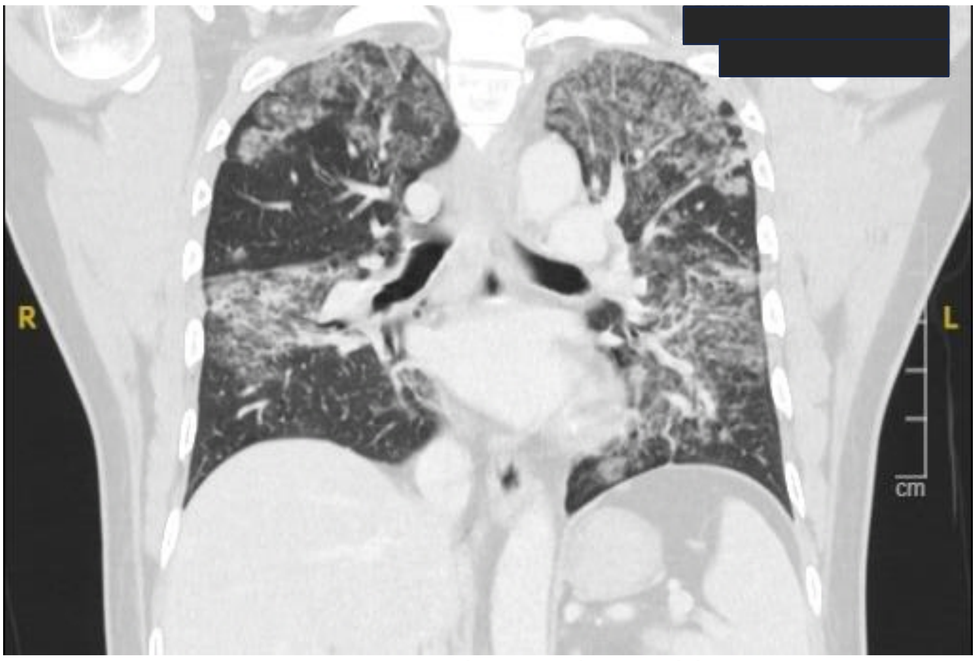

Figure 1: Computed tomography scan of thorax

Discussion

The BioRad Access HIV combo V2 is a semiquantitative paramagnetic-particle chemiluminescent immunoenzymatic assay (based on the sandwich principle) for the detection of HIV-1 p24 and HIV-2 p26 antigens. The increase in the S/CO following dilution of the sample points strongly to a high dose hook (prozone) effect where high concentrations of target analyte saturate capture antibodies and result in a reduced signal and falsely low results.

Conclusion

We speculate that very high concentrations of p24 antigen and/or anti-HIV-1 antibody in this patient may have resulted in a high dose hook effect and false negative results. He was started on antiretroviral medications and completed PJP treatment followed by secondary prevention. He remains well on regular follow up with Infectious Diseases. This case highlights a rare testing phenomenon in 4th-generation HIV screening assays.